

# Virtual Case for IMDRF Adverse Event Terminology Training

---

**Case serial: SCH-2024-01-01**

**Title: Silicon Levin tube, 14FR**

## Patient Condition

- A 45-year-old female patient was inserted with a 14Fr Levin tube in the intensive care unit. As the patient was thin, the physician selected a 14Fr tube rather than a 16Fr tube.
- To check that the Levin tube was located inside the stomach, the physician put air in using a syringe and subsequently observed with a stethoscope.
- To double-check that the Levin tube was properly placed in the patient's stomach, a chest X-ray was taken.

## Events

- The radiologist failed to find the Levin tube from the patient's chest X-ray image. Refer to Figure (a). Normally, the Levin tube would be observed in the chest X-ray image as shown in Figure (b).

Select the most appropriate IMDRF code for the above description.	
Annex A. Medical Device Problem	Annex G. Medical Device Component

## Post-event management & Health effects

- Removed the Levin tube for patient safety and inserted another 14Fr tube.
- The patient retook a chest X-ray to check for the right placement of the Levin tube.
- The patient expressed discomfort in the nose area due to repeated insertion.

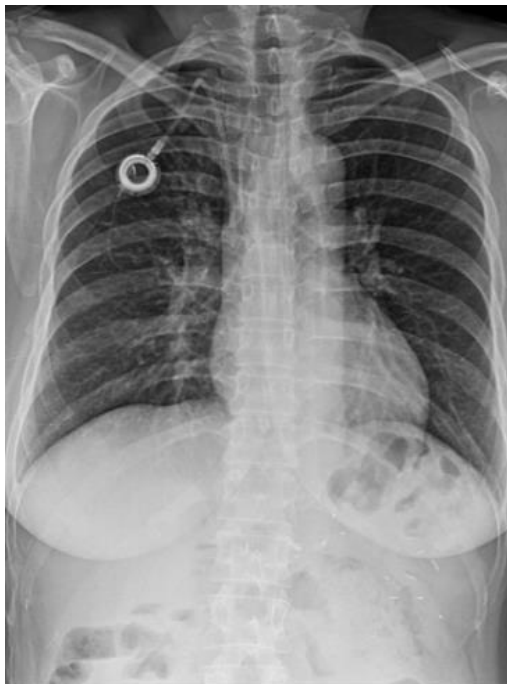Select the most appropriate IMDRF code for the above description.	
Annex E. Clinical Signs and Symptoms	Annex F. Health Impact

**Investigation (Cause, Improvements)**

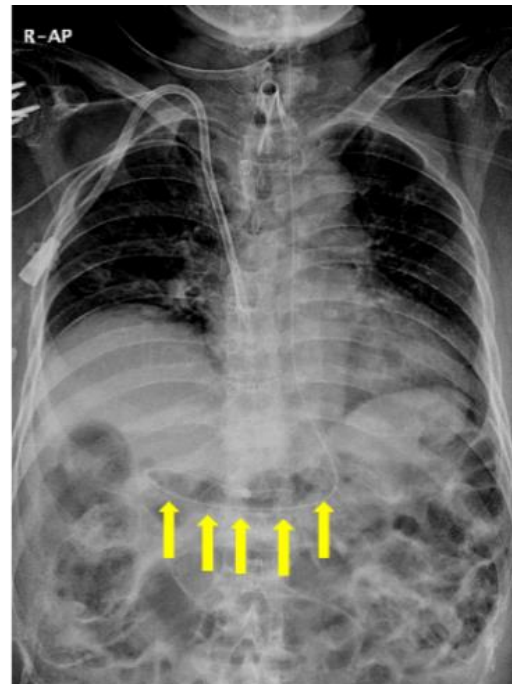
- Quality manager of the manufacturer detected that the radio-opaque line impregnated was narrower in width and contained smaller amount of barium sulfate at the tip, compared to the Levin tube of the same lot.
- The manufacturer decided to increase the width of the radio-opaque line to 8 mm for the Levin tube.

Select the most appropriate IMDRF code for the above description.		
Annex B. Type of Investigation	Annex C. Investigation Findings	Annex D. Investigation Conclusion

**Image**



(a) Patient's chest X-ray; failed to find Levin tube



(b) Chest X-ray; Levin tube normally inserted in stomach